

Techniques of Vascular Resection and Reconstruction in Pancreatic Cancer



George Younan, MD, Susan Tsai, MD, MHS, Douglas B. Evans, MD, Kathleen K. Christians, MD*

KEYWORDS

• Pancreaticoduodenectomy • Vascular resection • Vascular reconstruction • Whipple

KEY POINTS

- Accurate staging and stage-specific therapy are used by a multidisciplinary team.
- Neoadjuvant treatment response (in contrast to disease progression) is associated with increased survival duration and predicts successful surgery.
- Vascular resections, whether venous or arterial, must be planned events (in contrast to an intraoperative surprise) for best possible outcomes.
- In situations of cavernous transformation of the portal vein, diversion of mesenteric flow before beginning the portal dissection is critically important to the performance of a safe operation.
- Revascularization of the common hepatic artery during an Appleby procedure lowers the risk of biliary/hepatic ischemia and gastric atony.

INTRODUCTION

Vascular resection during pancreatectomy was performed within two decades from Whipple and coworkers¹ first description of pancreaticoduodenectomy (PD) in 1935. The concept of “regional pancreatectomy” subsequently led by Fortner in the early 1970s failed to improve outcomes because wide tissue and lymphatic clearance around the tumor did not improve patient survival.^{2–5} Vascular resections are currently performed to obtain an R0 margin during PD when the only area that prevents a gross complete resection of the tumor is vascular involvement otherwise amenable to

Conflict of Interest: None.

Pancreatic Cancer Program, Division of Surgical Oncology, Department of Surgery, Medical College of Wisconsin, 9200 W Wisconsin Ave, Milwaukee, WI 53226, USA

* Corresponding author. Department of Surgery, Medical College of Wisconsin, 9200 West Wisconsin Avenue, Milwaukee, WI 53226.

E-mail address: kchristi@mcw.edu

Surg Clin N Am 96 (2016) 1351–1370

<http://dx.doi.org/10.1016/j.suc.2016.07.005>

0039-6109/16/© 2016 Elsevier Inc. All rights reserved.

surgical.theclinics.com

reconstruction. Even in the pre-neoadjuvant treatment era, venous resections for isolated vein involvement conferred a 2-year survival benefit.^{6–8} After the American Hepato-Pancreato-Biliary Association/Society of Surgical Oncology consensus statement in 2009, PD with venous resection and reconstruction became the standard of care in the treatment of pancreatic adenocarcinoma.⁹ Arterial resection and reconstruction during PD was also part of the early regional pancreatectomy approach; however, enthusiasm for these procedures was lost because of technical difficulties of the operation, resulting in higher morbidity and mortality. With the improved surgical techniques available in specialized centers, arterial resections in appropriately selected patients have once again been adopted and proven to be safe.^{10–12}

In addition to technical advances in surgery, advances in systemic chemotherapy have also resulted in improved response rates and prolonged survival.^{13–18} Patients with borderline resectable pancreatic adenocarcinoma should be offered neoadjuvant systemic chemotherapy and/or chemoradiation based on all nationally recognized guidelines.^{16,18,19} Multiple centers are now also starting to offer neoadjuvant therapy for resectable pancreatic cancer, representing a shift in the treatment paradigm in recognition of significantly improved survival rates recently reported with this approach.¹⁷ The improved response rate to current chemotherapy regimens (FOLFIRINOX, gemcitabine-abraxane, GTX) has rendered patients, initially deemed unresectable, to be considered for resection.^{13,14} There are increasing numbers of reports touting the positive effect of neoadjuvant therapy on margin status, lymph node positivity, and tumor response.¹⁶ Neoadjuvant therapy allows for selection of patients with biologically responsive tumors to be considered for major vascular resection and reconstruction with curative intent.¹⁷

This article describes the technical aspects of these major operations, including accurate preoperative staging and planning, the technical aspects of venous and arterial resection and reconstruction during pancreatectomy, and key points of the perioperative care of these patients.

PREOPERATIVE PLANNING

Inherent in the planning for vascular resection during pancreatectomy is preoperative staging and the delineation of vascular involvement by the tumor. A computed tomography (CT)-based staging system for pancreatic cancer has been developed at the Medical College of Wisconsin and cited in national consensus guidelines (**Table 1**).^{9,20,21} A multidisciplinary team approach to any new diagnosis of pancreas cancer is the foundation of success.¹⁸ All team members follow the same principles to optimize and efficiently administer all intended parts of the treatment program. Key principles of this program are discussed next.

Clinical Staging

High-definition cross-sectional imaging is the mainstay for defining tumor-vessel relationships and aberrant vascular anatomy. Multidetector, dual-phase, contrast-enhanced CT provides accurate clinical staging based on reproducible anatomic relationships. The tumor is defined and classified as being resectable, borderline resectable, locally advanced A/B, or metastatic.¹³ In a resectable tumor, there is no evidence of arterial involvement (abutment or encasement) and tumor-induced narrowing of the portal vein (PV), superior mesenteric vein (SMV), or PV-SMV confluence, if present, is less than 50% (**Fig. 1**). Borderline resectable tumors include tumors with abutment of the superior mesenteric artery (SMA) and celiac artery (CA) of 180° or less and/or short-segment encasement of the common hepatic artery (CHA) amenable for

Table 1
CT-based staging system for pancreatic cancer from the Medical College of Wisconsin

	RPC	BRPC	LAPC-A	LAPC-B
Tumor-artery relationship	No arterial abutment of CA, SMA, or HA	CA/SMA abutment <180° HA abutment or short-segment encasement without CA involvement	SMA encasement >180° but <270° CA encasement >180° without involvement of aorta HA encasement involving the CA with target for reconstruction	SMA encasement >270° CA encasement >180° with involvement of aorta HA encasement involving the CA without target for reconstruction
Tumor-vein relationship	Vein (PV, SMV, PV-SMV) abutment and/or narrowing <50%	Vein (PV, SMV, PV-SMV) narrowing >50% with target for reconstruction	Vein (PV, SMV, PV-SMV) narrowing >50% without target for reconstruction	Vein (PV, SMV, PV-SMV) narrowing >50% without target for reconstruction
Extrapancreatic disease	No evidence of distant metastasis	Suspicious, nondiagnostic evidence of metastasis	No evidence of distant metastasis	No evidence of distant metastasis

Abbreviations: BRPC, borderline resectable pancreas cancer; CA, celiac artery; HA, hepatic artery; LAPC-A, locally advanced pancreas cancer type A; LAPC-B, locally advanced pancreas cancer type B; PV, portal vein; RPC, resectable pancreas cancer; SMA, superior mesenteric; SMV, superior mesenteric vein.

Data from Refs. [9,20,21](#)

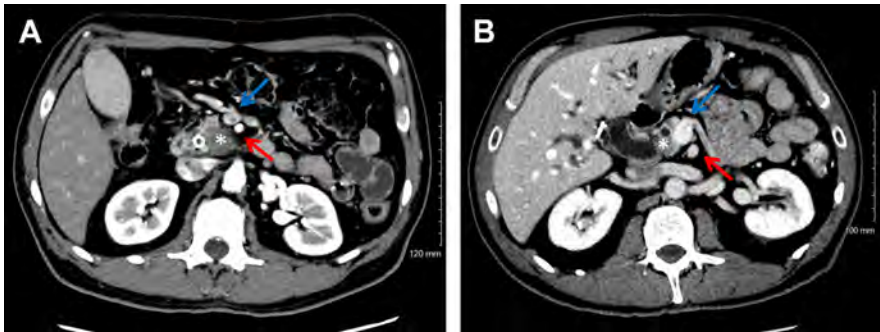


Fig. 1. Computed tomography axial images of resectable pancreas cancer. (A) Tumor in the uncinate process of the pancreas (*asterisk*); a fat plane is present between the tumor and the superior mesenteric artery (SMA, *red arrow*), and the SMV (*blue arrow*). (B) There is less than 50% lateral tumor abutment of the SMV and no extension to the SMA.

reconstruction. Tumors in this category also include those that narrow the SMV greater than 50% or those with short-segment occlusion of the PV, SMV, or SMV-PV confluence, with a proximal and distal venous target to allow for reconstruction. Patients who have indeterminate extrapancreatic lesions on CT scan that are worrisome, but not proven to be metastases, are also classified as borderline resectable tumors. Patients with a borderline performance status (surgical candidacy is a question at the time of diagnosis because of disease-related factors or patient comorbidities) are also considered borderline resectable because performance status alone has been correlated with disease progression and survival (**Fig. 2**).¹⁹ In locally advanced tumors, there is greater than 180° (encasement) of the SMA or CA, non-reconstructable hepatic artery encasement, or encasement/occlusion of the PV, SMV, or SMV-PV confluence that is not amenable to reconstruction. We recently further divided locally advanced tumors into types A and B. Type A tumors can potentially be resected after a favorable response to neoadjuvant treatment. These tumors have greater than 180° but less than 270° encasement of the SMA (pancreatic head and uncinate tumors), or greater than 180° encasement of the CA without involvement of the aorta (usually pancreatic body tumors). Anything beyond these parameters is classified as locally advanced type B, and patients with these tumors are not typically considered for surgery regardless of the extent of treatment response following neoadjuvant therapy (**Figs. 3 and 4**).

Tissue Diagnosis and Biliary Drainage

Initiation of chemotherapy or radiotherapy is based on a tissue diagnosis of cancer and normalization of liver function tests, in particular, serum bilirubin. Therefore, an experienced gastroenterology team with on-site cytopathology is required for an endoscopic ultrasound-guided fine-needle aspiration biopsy of the tumor. Once the tissue diagnosis is confirmed, endoscopic retrograde cholangiopancreatography with placement of a durable self-expandable metallic biliary stent is completed.²²

Restaging and Treatment Response

Patients are enrolled in stage-specific chemotherapy and/or chemoradiation protocols whenever possible. Patients with resectable pancreas cancer receive chemotherapy or chemoradiation before surgery. Patients with borderline resectable disease, by definition, have more advanced disease and require more complex operations. These

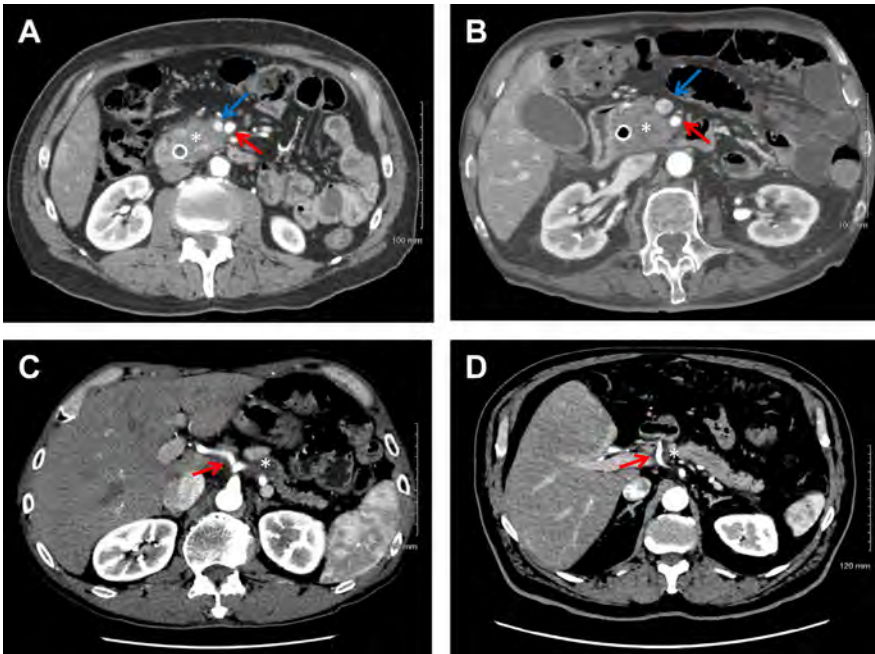


Fig. 2. Computed tomography axial images representing borderline resectable pancreas cancer. (A) Narrowing of greater than 50% of the SMV (*blue arrow*). (B) Abutment of the SMA (*red arrow*) of less than 180°. (C) CA (*red arrow*) abutment of less than 180°. (D) Short-segment encasement of the CHA (*red arrow*) amenable to reconstruction. Tumor is marked by *asterisk*.

patients are therefore treated with an extended period of induction therapy, usually including radiation. Most tumor-vessel relationships remain unchanged after neoadjuvant therapy despite a reduction in overall tumor size. Patients are evaluated and restaged with CT and tumor markers after completion of each phase of their neoadjuvant treatment program. Progression toward surgery depends on the favorable response of the disease (lack of distant disease progression) and the local tumor (absence of local progression and it is hoped a response as measured by a decrease in tumor diameter) to neoadjuvant therapy. We have defined treatment response based on three criteria: (1) clinical, (2) biochemical, and (3) radiographic response.

Patients are then classified into responders, nonresponders, and those with stable disease. Clinical assessment includes performance status and pain. We use serum levels of CA 19-9 for biochemical assessment of tumor response (additional serum markers are under active investigation). The CA 19-9 level is measured in all patients after diagnosis (and after normalization of their serum bilirubin) and is also rechecked at each restaging evaluation. A decrease in CA 19-9 levels has been associated with improved survival.^{23,24} An increase of CA 19-9 at restaging is often an accurate marker of disease progression. Clinicians should have a low threshold to expand the restaging work-up before surgery in the event of a rising CA 19-9. Finally, radiographic restaging is completed after each phase of neoadjuvant therapy (usually every 2 months) and before surgery (within 4 weeks of surgery) to reassess tumor-vessel relationships as a guide to the possible need for vascular resection/reconstruction. A CT scan is also required after any endoscopic intervention to assess for possible inflammatory (pancreatitis) changes post-endoscopic retrograde cholangiopancreatography that

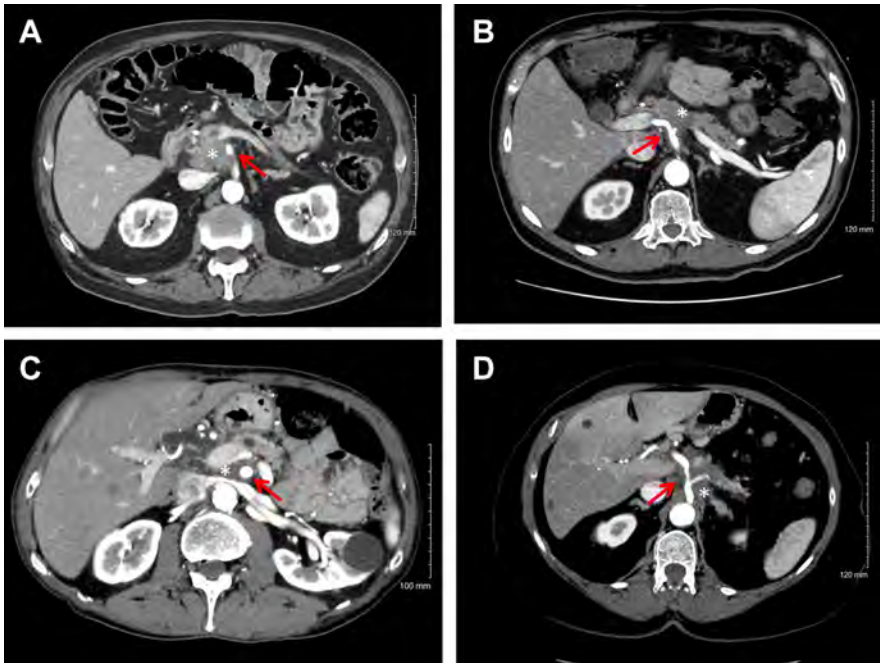


Fig. 3. Computed tomography axial images representing locally advanced pancreas cancer. (A) Locally advanced type A tumor with SMA (*arrow*) encasement greater than 180° but less than 270° . (B) Locally advanced type A tumor with celiac axis (*red arrow*) encasement greater than 180° without involvement of the aorta. (C) Locally advanced type B tumor with SMA (*arrow*) encasement greater than 270° . (D) Locally advanced type B tumor with celiac axis (*arrow*) encasement extending to the aorta. Tumor is marked by *asterisk*.

may delay surgery; we would never operate on a patient after an interventional procedure in the absence of a repeat CT scan.

Patients are seen in clinic for their final restaging just before surgery. Medical clearance with explicit definition and optimization of comorbidities is obtained with special

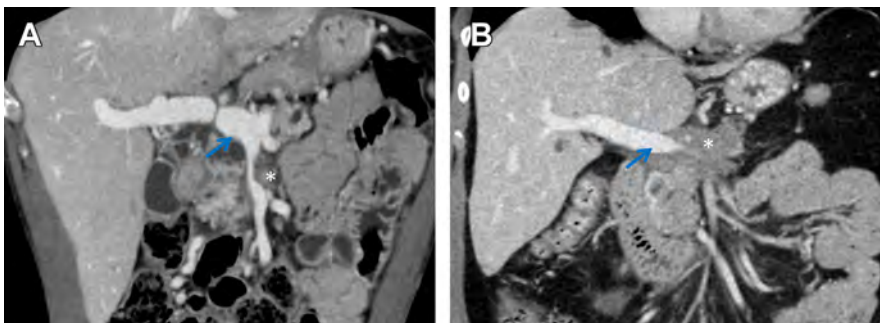


Fig. 4. Computed tomography coronal images representing encasement of the SMV and SMV-PV confluence. (A) Greater than 50% narrowing of the SMV-PV confluence (*arrow*) with a distal vein suitable for reconstruction. (B) Greater than 50% narrowing of the SMV-PV confluence, however without a distal vein that is suitable for reconstruction. Tumor is marked by *asterisk*.

reference to cardiac function. Attention is also paid to routine health maintenance and we prefer that patients have had a colonoscopy within the last 5 to 10 years based on personal/family history. Additional individualized imaging pertaining to specific clinical scenarios is obtained (ie, MRI or PET scans to rule out metastatic disease). Patients are consented for pancreatectomy and feeding jejunostomy tube insertion. Consent is also obtained for the harvest of the internal jugular vein and/or saphenous vein for vascular reconstruction. Venous mapping studies may be obtained preoperatively if needed. All patients undergo light bowel preparation the day before surgery.

SURGICAL APPROACH

Prophylactic antibiotics are given within an hour of the incision time. Central venous access is avoided in the left neck to preserve the internal jugular conduit for venous reconstruction. If the patients have power ports used for chemotherapy, these are accessed in the preoperative holding area for use during the operation. The left neck and groin are prepared along with the abdomen if vascular resection is anticipated. We perform a detailed “time out” procedure during which we review important tumor-vessel considerations and rereview the CT images. A detailed preoperative note completed by the attending surgeon reviews indications for surgery and the planned operative approach. A diagnostic laparoscopy is always performed before an open exploration to rule out extrapancreatic disease that is radiologically occult and thereby avoid an open laparotomy that provides no oncologic benefit to the patient.²⁵ Pancreatectomies are performed as we have described previously.²⁶ Nuances pertaining to anatomy and surgical techniques for vascular resection and reconstruction are described next.

Venous Resection and Reconstruction

Venous anatomy

Understanding the mesenteric venous anatomy during pancreatectomy is critical. The SMV joins the splenic vein posterior to the pancreas neck to form the PV. The SMV drains the midgut through two first-order branches; the proximal small bowel is drained by the jejunal branch and the distal small bowel and proximal colon are drained by the ileal branch. The jejunal branch normally arises from the posteromedial aspect of the SMV and courses posterior to the SMA, whereas the ileal branch travels in a cranial-caudal direction in the anterior root of the small bowel mesentery. The inferior mesenteric vein (IMV) drains the distal colon and travels in a cranial-caudal direction, just lateral to the ligament of Treitz, frequently joining the distal splenic vein. The IMV may, however, enter the SMV directly, just below the SMV-PV confluence. The common trunk of the SMV has two early anterior branches at the level of the transverse mesocolon: the middle colic vein and the gastroepiploic vein, which may arise separately, or together, as the gastrocolic trunk of Henle (**Fig. 5**).²⁷

Reconstruction guidelines: portal vein and superior mesenteric vein

When pancreatic tumors involve the PV, SMV, or PV-SMV confluence, venous resection and reconstruction are required.⁹ High-quality axial imaging with three-dimensional vascular reconstructions helps to accurately predict vascular involvement and allows the surgeon to plan the operation with the goal of avoiding intraoperative technical misadventures. The types of venous resection and reconstruction have been published^{8,28} and are classified as follows: lateral venorrhaphy and primary repair (VR0), tangential resection with saphenous vein patch (VR1), segmental resection with splenic vein ligation and either primary anastomosis (VR2) or an interposition

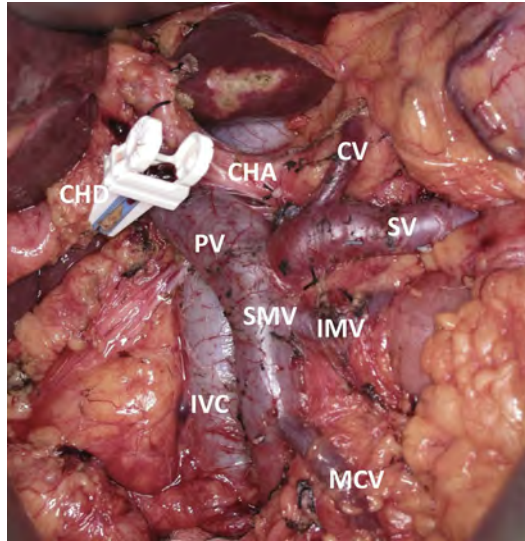


Fig. 5. Intraoperative photograph of mesenteric venous anatomy. In this particular patient, the IMV drains directly into the SMV. CHD, common hepatic duct; CV, coronary vein; IVC, inferior vena cava; MCV, middle colic vein; SV, splenic vein.

graft (VR3), or segmental resection with splenic vein preservation and either primary anastomosis (VR4) or an interposition graft (VR5) (**Fig. 6**).

At the time of operation, surgical judgment is used to decide if venous resection is needed or if the tumor in the pancreatic head can be separated from the PV, SMV, or

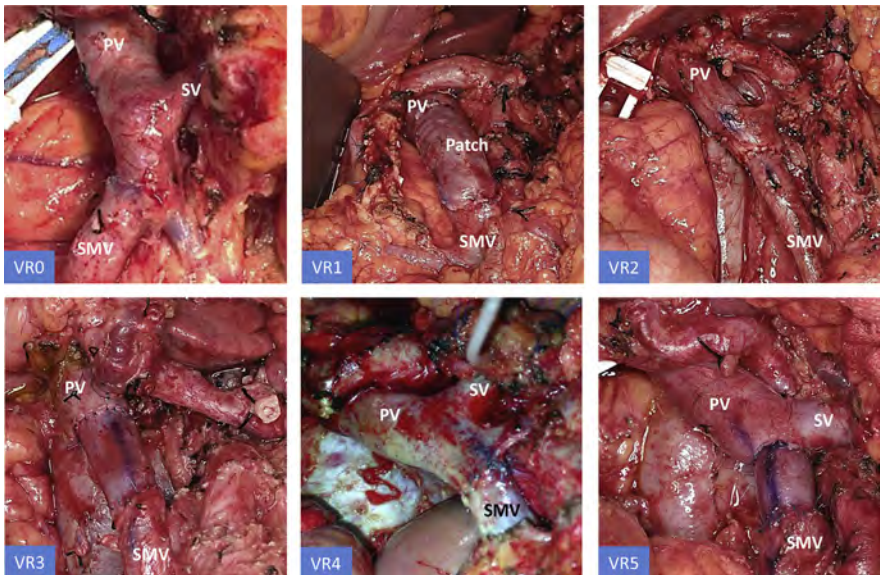


Fig. 6. Types of venous reconstructions: lateral venorrhaphy and primary repair (VR0), tangential resection with saphenous vein patch (VR1), segmental resection with splenic vein ligation and either primary anastomosis (VR2) or an interposition graft (VR3), or segmental resection with splenic vein preservation and either primary anastomosis (VR4) or an interposition graft (VR5).

the PV-SMV confluence without leaving residual disease on or within the vein. Sometimes this requires obtaining proximal and distal control followed by a trial dissection. If the tumor does not separate from the vein, then venous resection is needed. We frequently use an artery (SMA)-first approach, which requires cutting through tissue medial to the SMV down to the level of the SMA and removing all of the soft tissue to the right of the SMA (Fig. 7).²⁹ This leaves the PD specimen attached to the patient only at the site of tumor-vein adherence. Historically, this approach involved ligation of the splenic vein to not only gain improved access to the SMA but also to allow primary repair of the PV or SMV. If the splenic vein is preserved, an interposition graft is needed if the resected vein segment is more than 2 to 3 cm; otherwise, the reconstruction is often placed on undo tension (which can predispose to thrombosis and occlusion). Autologous vein harvesting adds time to the procedure. The left internal jugular vein harvest is technically straight forward, associated with minimal morbidity, and probably the quickest and easiest option (compared with the left renal vein or the saphenous vein). We do not use the left renal vein even though a second incision is not necessary, because the conduit frequently does not provide enough length for interposition grafting.³⁰ Proximal and distal control of the PV or SMV is obtained with vascular clamps positioned 2 to 3 cm above and below the level of intended resection. We routinely use inflow occlusion on the SMA and systemic heparinization during the repair to prevent small bowel edema, which would make the biliary and pancreatic reconstructions unnecessarily difficult.^{8,30} Vein reconstruction is completed with interrupted 6-0 prolene. The final result should consist of a near perfect size match of the interposition graft between the proximal and distal venous targets and tension-free anastomoses. When a patch is used, it must match the contour and size of the initial resected vein.³⁰ We want to emphasize the need for perfection in venous reconstruction; this is a low-flow system that results in thrombosis if not done well (Fig. 8).

Splenorenal shunting

The splenic vein may require ligation when (1) the SMV-PV confluence is encased by tumor, (2) the splenic vein is ligated for improved exposure of the proximal SMA, or (3) when increased length is needed for primary anastomosis of the SMV to the PV.³¹

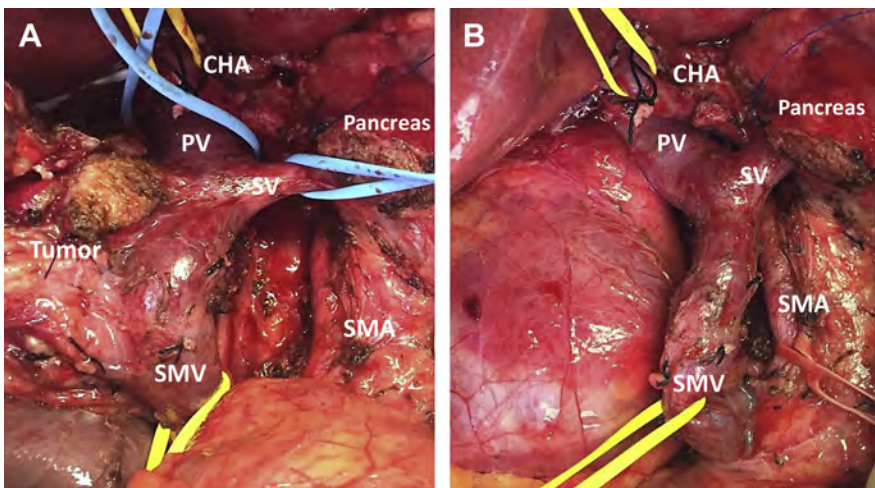


Fig. 7. An artery first approach was used to safely resect a tumor adherent to the portal vein (PV). (A) Tumor attached to the SMV. (B) View of the same anatomy after the tumor has been removed.

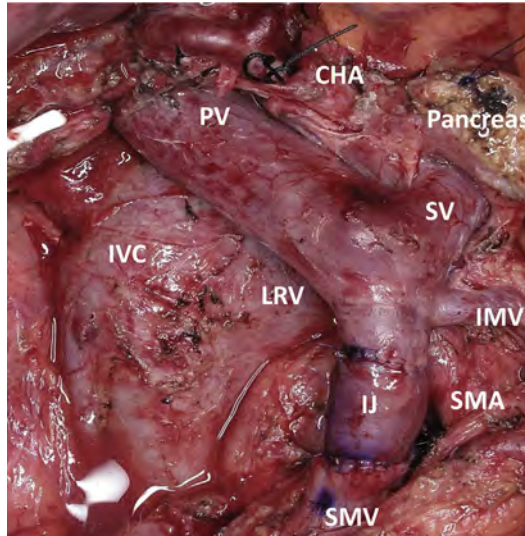


Fig. 8. Perfection in venous reconstruction is emphasized in this picture delineating a near perfect size match of the interposition graft between the proximal and distal venous targets and a tension-free anastomosis. IJ, internal jugular vein graft.

The IMV usually drains into the splenic vein but can empty into the SMV at or just below the SMV-PV confluence, in up to 30% of patients. When the splenic vein is ligated, blood flow returning from the spleen is usually diverted through the IMV (retrograde) away from the spleen to decompress the splenic vein. However, when the IMV does not empty into the splenic vein, splenic vein ligation can result in gastric and esophageal varicosities and sinistral portal hypertension; a risk factor for upper gastrointestinal hemorrhage. We usually avoid reanastomosis of the splenic vein to the reconstructed SMV-PV confluence because this may add tension and/or cause distortion of the repair. Thus, when the IMV does not enter the splenic vein (and splenic vein ligation is necessary), we have created a distal splenic vein to left renal vein anastomosis referred to as the splenorenal shunt of Warren.³² The end of the splenic vein is anastomosed to the side of the left renal vein allowing for decompression of the splenic circulation and thereby avoiding sinistral portal hypertension.^{8,31} However, we ligate the splenic vein only when necessary; we prefer to preserve the PV-splenic vein confluence when it is not involved by tumor because we believe that this leads to augmentation of portal flow and increased long-term graft patency rates (Fig. 9).³⁰

Portal venous cavernous transformation and mesocaval shunting

Chronic (in contrast to acute/immediate) PV occlusion causes cavernous transformation of the PV and creation of large venous collaterals around the pancreatic head, which pose a significant bleeding risk. Venous resection in this setting adds technical complexity to PD for an otherwise operable pancreatic tumor.³³ In this scenario, we have used mesocaval shunting to safely divert all mesenteric blood flow before attempting the portal dissection. Early in the procedure, but after the SMV is identified below the pancreatic neck (an area usually free of varices), the left internal jugular vein is harvested. A temporary mesocaval shunt is then created between the infra-pancreatic SMV and the adjacent inferior vena cava, using an IJ interposition graft (Fig. 10).^{33,34}

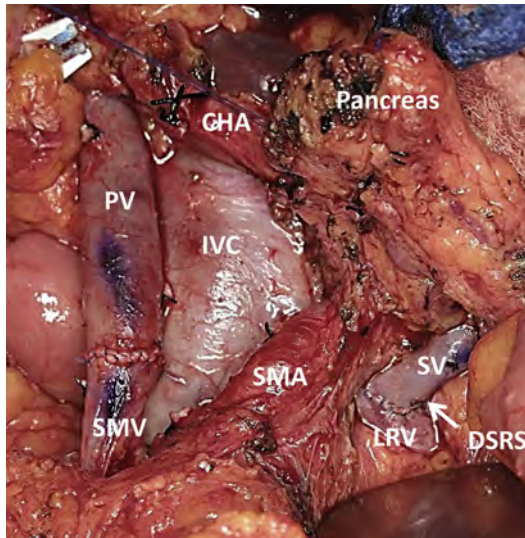


Fig. 9. A distal splenorenal shunt (DSRS, *white arrow*) is created by ligating the SV at the PV-SMV confluence and sewing the SV into the left renal vein (LRV).

Additional procedures may be necessary to control mesenteric blood flow, including early splenic artery ligation when performing a total pancreatectomy, or preoperative splenic artery embolization if direct access to the splenic vein is thought to be too difficult at the time of operation; the goal is total diversion of portal flow until the specimen is removed. The bile duct, PV, and other associated structures may also be stapled to decrease blood loss during the tumor resection. It is important to mention that each step of this complicated operation is carefully planned preoperatively to avoid any surgical misadventure and result in the best possible outcome.

Management of jejunal and ileal branches of the superior mesenteric vein

Variations of the venous anatomy are common and add complexity to the procedure. In 20% of the population, the jejunal branch crosses anterior, as opposed to posterior, to the SMA. An anterior jejunal vein provides easier access to the vein in cases of tumor involvement, but is usually associated with other venous anomalies. These variations may include the lack of a main SMV trunk, drainage of the IMV directly into the jejunal branch, or variable inferior pancreaticoduodenal venous branches arising from the ileal branch of the SMV. As a general rule, one of the two first-order SMV branches, whether the jejunal branch or the ileal branch, may be sacrificed without the need for reconstruction if it is encased by tumor and if the other branch is of appropriate caliber for reconstruction. For example, we usually prefer that the ileal branch be larger in transverse diameter than the SMA (as seen on preoperative axial imaging) to improve patency of the SMV-PV reconstruction (the distal venous target should be 1.5 times the diameter of the SMA if possible). When ligation of one of the first-order SMV branches is required during PD, it adds significantly to the complexity of the operation. If interposition grafting is needed, we use the internal jugular vein for the conduit and the ileal branch is always preferred for the distal target (as opposed to the jejunal branch). The ileal branch has a thicker wall relative to the jejunal branch and its anatomic location facilitates a safe distal anastomosis. In contrast, the jejunal branch in its usual anatomic location courses posterior to the SMA.²⁷ Ligation of both of these

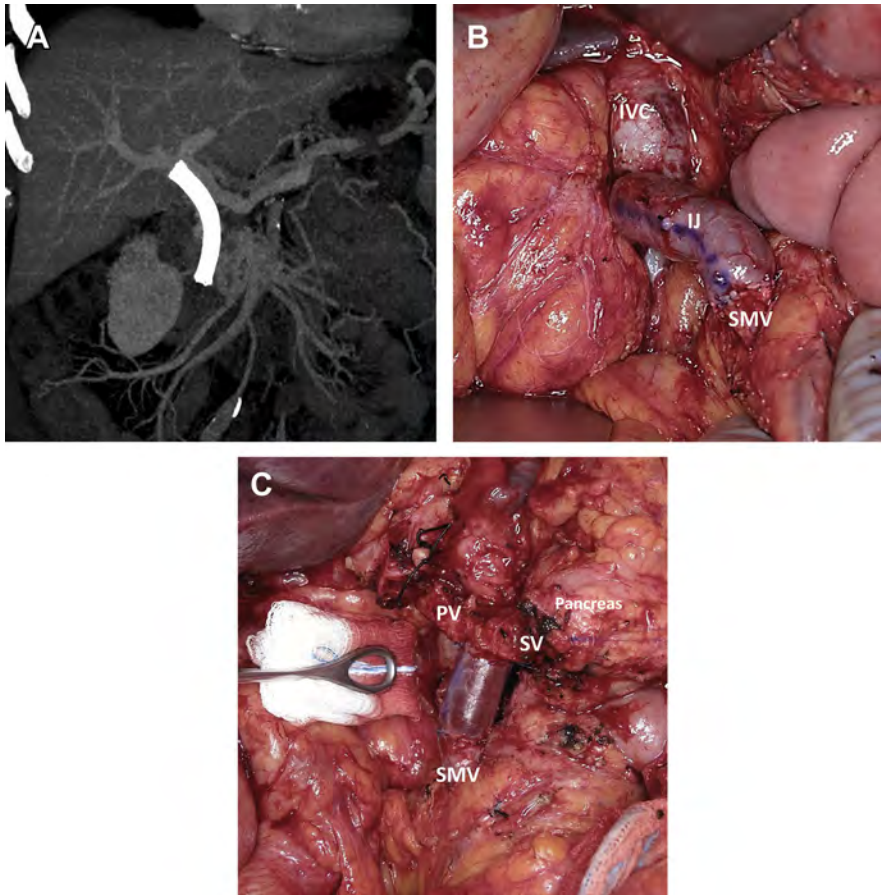


Fig. 10. (A) Preoperative computed tomography coronal image of the abdomen demonstrating the mesenteric venous anatomy and cavernous transformation of the PV. (B) An IJ vein is used as a temporary mesocaval shunt during pancreaticoduodenectomy. (C) IJ vein being used as an interposition graft between the SMV and the PV after removal of the specimen.

branches is not tolerated when the pancreatic head and accompanying venous collaterals are removed and results in acute bowel ischemia and necrosis (**Fig. 11**).²⁶

Arterial Resection and Reconstruction

Arterial anatomy

Although venous resection and reconstruction is now routinely done for pancreatic cancer, arterial resection continues to be an area of significant controversy. Patients with arterial involvement, who were previously considered unresectable, are now selectively being considered for resection if they show adequate response to induction therapy.¹⁰ Arterial abutment of the SMA or the CA, or even short-segment encasement of the CHA, are considered in the category of borderline resectable tumors.¹³ Planned arterial resection is performed with acceptable outcomes when done in appropriately selected patients and may improve long-term survival.¹⁰

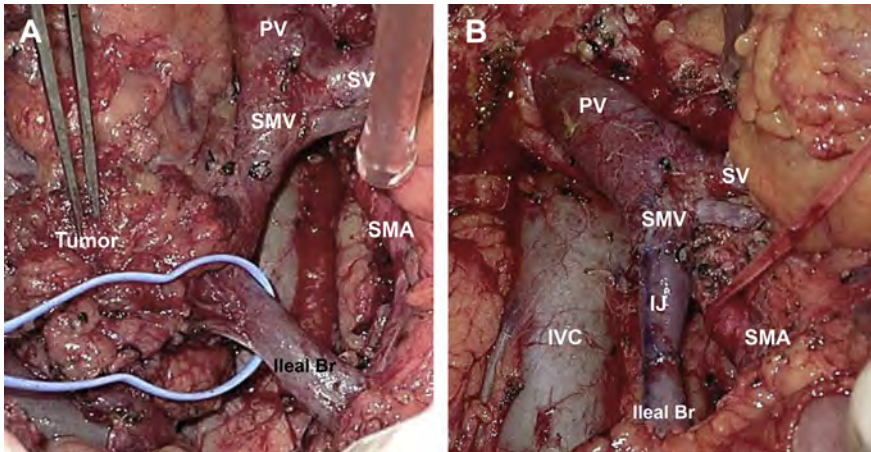


Fig. 11. Intraoperative photograph of a pancreatic tumor involving the inferior part of the SMV. (A) Tumor still attached after ligation of the first jejunal branch. The tumor was resected en bloc with a part of the inferior SMV. (B) IJ graft used to reconstruct the ileal branch into the SMV.

Visceral arteries are circumferentially covered by a perineural sheath, which is not present around visceral mesenteric veins. Tumors that involve this sheath tend to spread longitudinally through this neural layer. There is a natural plane between the arterial adventitia and this nerve sheath, which allows resection of the tumor without arterial resection in many patients. Additionally, preoperative chemoradiation has been shown to sterilize the periphery of these tumors, resulting in R0 margins even in the presence of arterial abutment.^{13,16,35} One caveat to this finding is when a tumor encases the whole circumference of an artery; dissection then requires cutting through tumor to reach this per-adventitial plane, which is considered oncologically unacceptable (at least at the time that this article is being written, understanding the rapidly changing environment of pancreatic cancer treatment).¹³

Superior mesenteric artery

The SMA margin is undoubtedly the most technically challenging and the most commonly positive margin following PD and, therefore, the most common site of local disease recurrence. High-quality preoperative axial imaging is accurate in defining the tumor-artery relationship. Steps of the dissection of the SMA margin have been previously published by our group.²⁶ We classify SMA abutment of 180° or less as being borderline resectable, and encasement of greater than 180° to be locally advanced, with a recent subclassification of the locally advanced tumors into type A and type B. Type A tumors have encasement of the SMA greater than 180° but less than or equal to 270° . These tumors are potentially operable if they respond to neoadjuvant therapy. The one caveat is the morbidity of skeletonization of the SMA at the time of operation. This may result in rapid gastrointestinal transit caused by denervation of the mid-gut as the autonomic nerves that regulate small bowel motility are divided. Total parenteral nutrition may be required along with agents to slow gastrointestinal motility. SMA resection and reconstruction is not yet considered acceptable in pancreas cancer surgery because of risk of intestinal ischemia and death and the profound nutritional depletion that would occur in most patients (because of complete denervation of the entire mid-gut (Fig. 12)).¹³

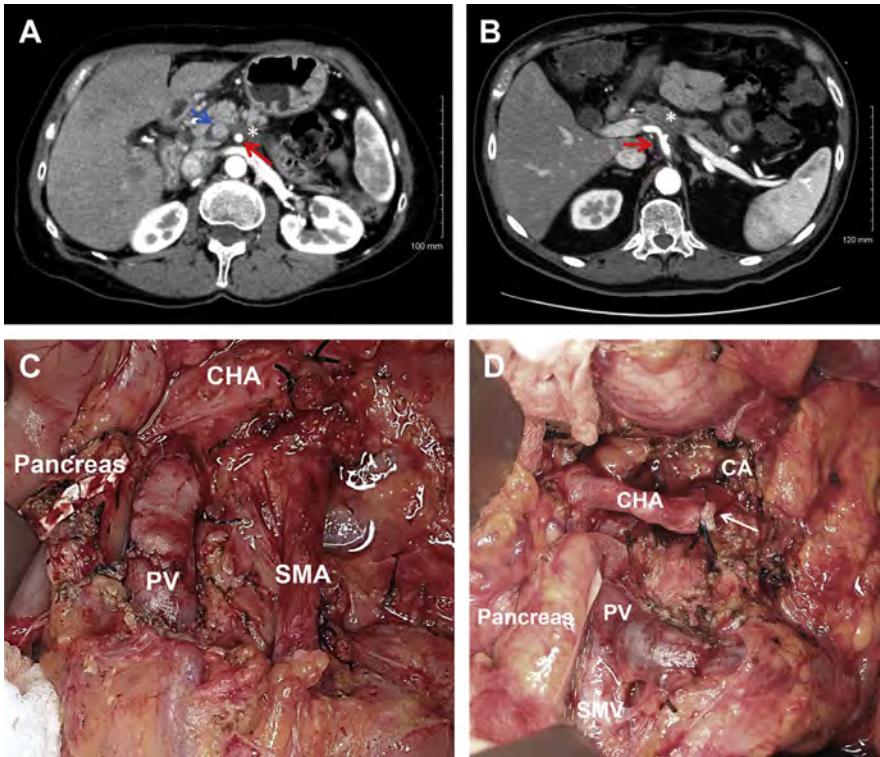


Fig. 12. (A) Computed tomography axial image of a locally advanced type A tumor involving greater than 180° of the SMA, (blue arrow) SMV, (red arrow) SMA, (asterisk) tumor. (B) Locally advanced type A tumor involving greater than 180° of the CA. Both tumors were microdissected off the SMA and the CA, respectively, (red arrow) celiac axis, (asterisk) tumor. (C, D) Intraoperative photographs of the respective tumors after being resected; arrow points to the splenic artery stump.

Celiac artery

The Appleby procedure evolved as an answer to the question of resection of the CA because of tumor encasement.^{12,36} Patients with cancers of the pancreatic body being considered for celiac axis resection must manifest disease stability or improvement following neoadjuvant therapy.¹⁰ Resection of pancreatic body tumors with concurrent celiac axis resection relies on retrograde blood flow through the gastroduodenal artery (GDA) and the pancreatic arcade, providing hepatic arterial blood flow through the proper hepatic artery and gastric perfusion through the right gastric and right gastroepiploic arteries. Preoperative CT imaging is of major importance in surgical planning for these procedures. We prefer a “supercharged” Appleby procedure when the celiac axis is resected.¹⁰ A reversed saphenous vein graft is used as an interposition graft between the CA stump and the distal CHA before it divides into the GDA and the proper hepatic artery. Interposition grafting augments hepatic and gastric blood flow and may enhance gastric emptying. Supercharging theoretically prevents delayed gastric emptying resulting from relative gastric ischemia when the left gastric artery needs to be resected with the CA.¹⁰ The presence of a replaced right hepatic artery during an Appleby procedure would preclude the need for supercharging the hepatic arterial flow but would obviously not affect gastric perfusion; if the left gastric

artery is resected, some degree of gastric atony may occur in the absence of a larger head of pressure in the right gastric and right gastroepiploic arteries (**Fig. 13**).¹⁰

In cases of CA stenosis, it is critically important when performing PD to test the hepatic arterial flow with compression of the GDA before ligation of this artery. If the flow in the CHA is diminished or absent with a test clamp of the GDA, the celiac axis is dissected and freed from a compressing median arcuate ligament (which is usually the cause). If this does not improve blood flow, then a reversed saphenous vein interposition graft is used to augment hepatic arterial flow.²⁶

Common hepatic artery and anatomic variations

Encasement of a short segment of the CHA is classified as borderline resectable disease if arterial reconstruction is possible. This is usually encountered with tumors of the head or neck of the pancreas that require PD. We use a reversed saphenous vein graft to reconstruct the CHA.¹⁰ This interposition graft is anastomosed to the CHA stump arising from the celiac axis (**Fig. 14**). We have also used the right renal artery as an inflow source to revascularize the CHA if the CHA stump is friable and not useable; the aorta can also be used as an inflow source (**Fig. 15**).

Variations in mesenteric arteries are a common occurrence and plans should be made preoperatively to address anomalies should the need arise. Preoperative imaging is critical to allow for accurate assessment of the hepatic arterial anatomy including replaced or accessory right hepatic arteries arising from the SMA. Such vessels travel posterior to the PV and common bile duct and they may abut the tumor, although they most commonly course cephalad to the pancreas and associated neoplasm. An accessory right hepatic artery can be ligated without any consequence; however, a replaced right hepatic artery should be revascularized (**Fig. 16**). The same principle also applies to a replaced CHA where all of the blood flow to the liver is derived from the SMA. Proximal bile duct perfusion comes from the hepatic arterial system (usually the right hepatic artery) and therefore to prevent ischemia to a newly formed biliary-enteric anastomosis, revascularization of the CHA (or right hepatic artery) is required.

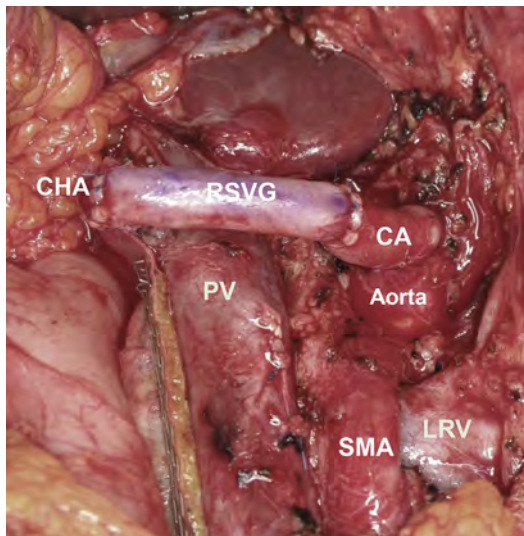


Fig. 13. Intraoperative photograph of a supercharged Appleby procedure where a reversed saphenous vein graft (RSVG) is used between the CA stump and the CHA.

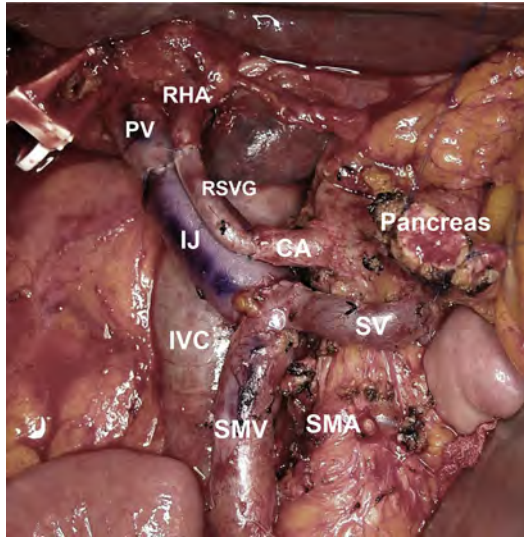


Fig. 14. Intraoperative photograph of a revascularization of the right hepatic artery (RHA) from the CA stump using an RSVG.

For reconstruction, we have most commonly used a reversed saphenous vein graft as an interposition graft between the proximal and distal parts of the resected vessel.^{10,26}

POSTOPERATIVE CARE

Postpancreatectomy patients are most commonly admitted to the surgical ward the day of surgery with the exception of patients who undergo total pancreatectomy, whom we prefer to watch one night in the surgical intensive care unit for blood sugar

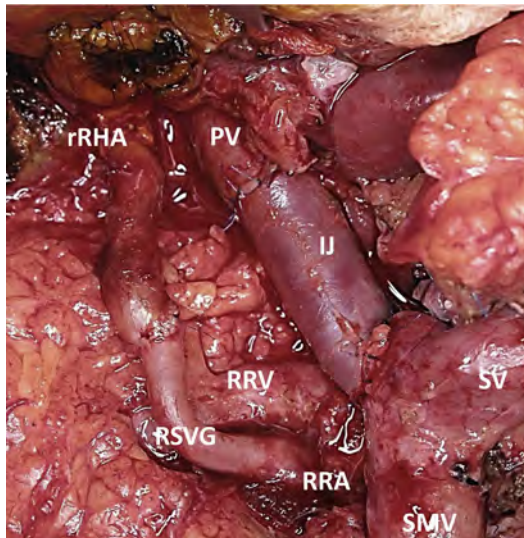


Fig. 15. Intraoperative photograph of a revascularization of a replaced right hepatic artery (rRHA) from the right renal artery (RRA) using an RSVG.

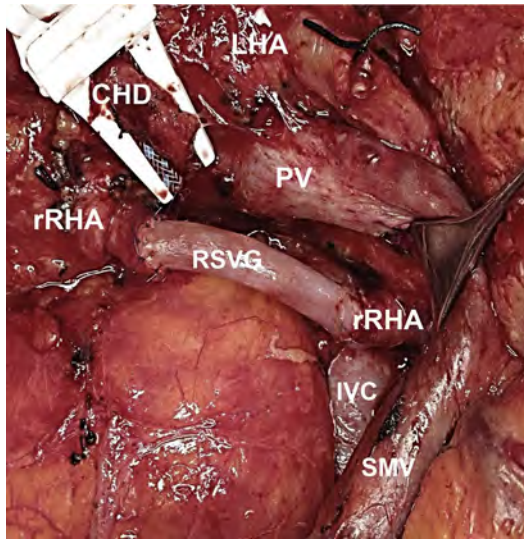


Fig. 16. Intraoperative photograph of a revascularization of a replaced rRHA using an RSVG.

monitoring. The average hospital stay on the surgical floor is 7 to 8 days. A postpancreatectomy pathway for PD patients has been used for many years and provides clear expectations for recovery on a daily basis. Patients are placed on a pain protocol regimen consisting of a patient-controlled anesthesia pump, scheduled oral gabapentin, and intravenous acetaminophen. Scheduled ketorolac is also given starting on postoperative Day 1 after proof of adequate renal function and stable blood counts. The intravenous pain regimen is switched to an enteral route, whether given orally or as a solution through the feeding jejunostomy tube following return of bowel function. All patients receive a soft nasogastric tube during surgery that is usually removed on postoperative Day 2 or 3. In patients showing early signs of delayed gastric emptying, promotility agents may be used as needed. The diet is then advanced daily from clear liquids to full liquids to a low-residue diet. Most of our patients have feeding jejunostomy tubes placed at the time of PD or total pancreatectomy and enteral feeds are started as early as the second postoperative day at a very slow rate.

Thrombosis of the vascular reconstruction rarely occurs in the acute postoperative setting if the surgery is done correctly. However, thrombosis may occur over time, with or without the appearance of disease recurrence. Most published series report 80% to 90% long-term patency rates of autologous conduits.^{6,30,37} We reported a 90% 1-year patency rate in 43 patients who had venous resection and reconstruction.³⁰ There are no guidelines, however, on the optimal pharmacologic management of patients after vascular resection and reconstruction. Our patients receive 300 mg of aspirin rectally, and prophylactic heparin (5000 units two or three times a day), beginning on postoperative day zero. Enteric coated oral aspirin is initiated once the patients are started on a diet and they are discharged home on 325 mg/day; the heparin is discontinued at the time of hospital discharge.

SUMMARY

Vascular resection and reconstruction during pancreatectomy add to the level of complexity of a procedure known to require mastery of surgical technique. With the

increase in the number of venous resections during PD and the acceptance and safety of arterial resections, the pancreas surgeon is required to select the appropriate patient and medically optimize them, understand and plan the procedure preoperatively, prepare the site of a vascular conduit to be harvested, and have sufficient skills in vascular surgery to perform complex vascular work as it pertains to pancreatectomy. The incorporation of newer systemic chemotherapy protocols in the treatment of pancreas cancer has led to an improvement in survival of affected patients; when such therapies are given before surgery, more patients with complex tumor-vessel anatomy are being considered for surgery. Importantly, complex pancreatic surgery for cancer, especially operations that involve vascular resection and reconstruction, should be considered only as part of a clearly defined multidisciplinary approach to this disease.

REFERENCES

1. Whipple AO, Parsons WB, Mullins CR. Treatment of carcinoma of the ampulla of Vater. *Ann Surg* 1935;102(4):763–79.
2. Yeo CJ, Cameron JL, Lillmoie KD, et al. Pancreaticoduodenectomy with or without distal gastrectomy and extended retroperitoneal lymphadenectomy for periampullary adenocarcinoma. Part 2: randomized controlled trial evaluating survival, morbidity, and mortality. *Ann Surg* 2002;236(3):355–66 [discussion: 366–8].
3. Farnell MB, Pearson RK, Sarr MG, et al. A prospective randomized trial comparing standard pancreatoduodenectomy with pancreatoduodenectomy with extended lymphadenectomy in resectable pancreatic head adenocarcinoma. *Surgery* 2005;138(4):618–28 [discussion: 628–30].
4. Nguyen TC, Sohn TA, Cameron JL, et al. Standard vs. radical pancreaticoduodenectomy for periampullary adenocarcinoma: a prospective, randomized trial evaluating quality of life in pancreaticoduodenectomy survivors. *J Gastrointest Surg* 2003;7(1):1–9 [discussion: 9–11].
5. Pedrazzoli S, DiCarlo V, Dionigi R, et al. Standard versus extended lymphadenectomy associated with pancreatoduodenectomy in the surgical treatment of adenocarcinoma of the head of the pancreas: a multicenter, prospective, randomized study. Lymphadenectomy Study Group. *Ann Surg* 1998;228(4):508–17.
6. Tseng JF, Raut CP, Lee JE, et al. Pancreaticoduodenectomy with vascular resection: margin status and survival duration. *J Gastrointest Surg* 2004;8(8):935–49 [discussion: 949–50].
7. Raut CP, Tseng JF, Sun CC, et al. Impact of resection status on pattern of failure and survival after pancreaticoduodenectomy for pancreatic adenocarcinoma. *Ann Surg* 2007;246(1):52–60.
8. Christians KK, Lal A, Pappas S, et al. Portal vein resection. *Surg Clin North Am* 2010;90(2):309–22.
9. Evans DB, Farnell MB, Lillmoie KD, et al. Surgical treatment of resectable and borderline resectable pancreas cancer: expert consensus statement. *Ann Surg Oncol* 2009;16(7):1736–44.
10. Christians KK, Pilgrim CH, Tsai S, et al. Arterial resection at the time of pancreatectomy for cancer. *Surgery* 2014;155(5):919–26.
11. Aosasa S, Nishikawa M, Noro T, et al. Total pancreatectomy with celiac axis resection and hepatic artery restoration using splenic artery autograft interposition. *J Gastrointest Surg* 2016;20(3):644–7.

12. Yamamoto Y, Sakamoto Y, Ban D, et al. Is celiac axis resection justified for T4 pancreatic body cancer? *Surgery* 2012;151(1):61–9.
13. Evans DB, George B, Tsai S. Non-metastatic pancreatic cancer: resectable, borderline resectable, and locally advanced—definitions of increasing importance for the optimal delivery of multimodality therapy. *Ann Surg Oncol* 2015;22(11):3409–13.
14. Evans DB, Ritch PS, Erickson BA. Neoadjuvant therapy for localized pancreatic cancer: support is growing? *Ann Surg* 2015;261(1):18–20.
15. Christians KK, Evans DB. Additional support for neoadjuvant therapy in the management of pancreatic cancer. *Ann Surg Oncol* 2015;22(6):1755–8.
16. Christians KK, Tsai S, Mahmoud A, et al. Neoadjuvant FOLFIRINOX for borderline resectable pancreas cancer: a new treatment paradigm? *Oncologist* 2014;19(3):266–74.
17. Christians KK, Heimler JW, George B, et al. Survival of patients with resectable pancreatic cancer who received neoadjuvant therapy. *Surgery* 2016;159(3):893–900.
18. Evans DB, Crane CH, Charnsangavej C, et al. The added value of multidisciplinary care for patients with pancreatic cancer. *Ann Surg Oncol* 2008;15(8):2078–80.
19. Katz MH, Pisters PW, Evans DB, et al. Borderline resectable pancreatic cancer: the importance of this emerging stage of disease. *J Am Coll Surg* 2008;206(5):833–46 [discussion: 846–8].
20. Appel BL, Tolat P, Evans DB, et al. Current staging systems for pancreatic cancer. *Cancer J* 2012;18(6):539–49.
21. Tempero MA, Malafa MP, Behrman SW, et al. Pancreatic adenocarcinoma, version 2.2014: featured updates to the NCCN guidelines. *J Natl Compr Canc Netw* 2014;12(8):1083–93.
22. Aadam AA, Evans DB, Khan A, et al. Efficacy and safety of self-expandable metal stents for biliary decompression in patients receiving neoadjuvant therapy for pancreatic cancer: a prospective study. *Gastrointest Endosc* 2012;76(1):67–75.
23. Katz MH, Varadhachary GR, Fleming JB, et al. Serum CA 19-9 as a marker of resectability and survival in patients with potentially resectable pancreatic cancer treated with neoadjuvant chemoradiation. *Ann Surg Oncol* 2010;17(7):1794–801.
24. Aldakkak M, Christians KK, Krepline AN, et al. Pre-treatment carbohydrate antigen 19-9 does not predict the response to neoadjuvant therapy in patients with localized pancreatic cancer. *HPB (Oxford)* 2015;17(10):942–52.
25. Jayakrishnan TT, Nadeem H, Groeschl RT, et al. Diagnostic laparoscopy should be performed before definitive resection for pancreatic cancer: a financial argument. *HPB (Oxford)* 2015;17(2):131–9.
26. Christians KK, Tsai S, Tolat PP, et al. Critical steps for pancreaticoduodenectomy in the setting of pancreatic adenocarcinoma. *J Surg Oncol* 2013;107(1):33–8.
27. Katz MH, Fleming JB, Pisters PW, et al. Anatomy of the superior mesenteric vein with special reference to the surgical management of first-order branch involvement at pancreaticoduodenectomy. *Ann Surg* 2008;248(6):1098–102.
28. Tseng JF, Tamm EP, Lee JE, et al. Venous resection in pancreatic cancer surgery. *Best Pract Res Clin Gastroenterol* 2006;20(2):349–64.
29. Leach SD, Davidson BS, Ames FC, et al. Alternative method for exposure of the retropancreatic mesenteric vasculature during total pancreatectomy. *J Surg Oncol* 1996;61(2):163–5.

30. Krepline AN, Christians KK, Duelge K, et al. Patency rates of portal vein/superior mesenteric vein reconstruction after pancreatectomy for pancreatic cancer. *J Gastrointest Surg* 2014;18(11):2016–25.
31. Pilgrim CH, Tsai S, Tolat P, et al. Optimal management of the splenic vein at the time of venous resection for pancreatic cancer: importance of the inferior mesenteric vein. *J Gastrointest Surg* 2014;18(5):917–21.
32. Warren WD. Cirrhosis and portal hypertension: selection of patients for shunt and shunt for the patient. *Am J Dig Dis* 1964;9:906–17.
33. Christians KK, Riggle K, Keim R, et al. Distal splenorenal and temporary mesocaval shunting at the time of pancreatectomy for cancer: initial experience from the Medical College of Wisconsin. *Surgery* 2013;154(1):123–31.
34. Pilgrim CH, Tsai S, Evans DB, et al. Mesocaval shunting: a novel technique to facilitate venous resection and reconstruction and enhance exposure of the superior mesenteric and celiac arteries during pancreaticoduodenectomy. *J Am Coll Surg* 2013;217(3):e17–20.
35. Kang CM, Chung YE, Park JY, et al. Potential contribution of preoperative neoadjuvant concurrent chemoradiation therapy on margin-negative resection in borderline resectable pancreatic cancer. *J Gastrointest Surg* 2012;16(3):509–17.
36. Appleby LH. The coeliac axis in the expansion of the operation for gastric carcinoma. *Cancer* 1953;6(4):704–7.
37. Chu CK, Farnell MB, Nguyen JH, et al. Prosthetic graft reconstruction after portal vein resection in pancreaticoduodenectomy: a multicenter analysis. *J Am Coll Surg* 2010;211(3):316–24.